

# Unusually Early Presentation of Small-Bowel Adenocarcinoma in a Patient With Peutz-Jeghers Syndrome

Michael F. Wangler, MD,\* Rishikesh Chavan, MD,† M. John Hicks, MD, PhD, DDS,‡§  
 Jed G. Nuchtern, MD,¶ Madhuri Hegde, PhD,# Sharon E. Plon, MD, PhD,\*||  
 and Patrick A. Thompson, MD†

**Summary:** Peutz-Jeghers syndrome (PJS) is an autosomal dominant cancer predisposition syndrome characterized by melanotic macules and hamartomatous polyps. Small-bowel surveillance in the pediatric PJS population is not designed to identify small-bowel malignancy, which is thought to arise in adulthood. A 13-year-old boy presented with lead-point intussusception, requiring emergent surgical resection. A mucinous adenocarcinoma was found arising from high-grade dysplasia within a polyp. On the basis of these findings and mucosal pigmentation, he was diagnosed with PJS. DNA sequencing revealed a heterozygous c.921-1G > T *STK11* mutation. This case is the earliest onset of small-bowel carcinoma in PJS, an observation relevant to surveillance guidelines.

**Key Words:** Peutz-Jeghers syndrome, *STK11*, small-bowel adenocarcinoma, lead-point intussusception, cancer surveillance

(*J Pediatr Hematol Oncol* 2013;35:323–328)

## BACKGROUND

Peutz-Jeghers syndrome (PJS) is an autosomal dominant cancer predisposition syndrome characterized by melanotic pigmented macules, hamartomatous polyps, and an increased risk of cancer.<sup>1</sup> The unusual pigmentation on the lips and its inherited nature has been clinically known since the report of “Hutchinson’s twins” by British physicians Connor and Hutchinson, a finding which was assumed to be a curiosity.<sup>1</sup> However, its relationship to cancer risk was suggested when one of these twins subsequently died of intestinal obstruction and the other of breast cancer. In 1949, Jeghers et al<sup>2</sup> proposed that a single pleiotropic gene was likely responsible for this cancer predisposition syndrome. The diagnostic criteria of PJS are based on the clinical findings and require the presence of hamartomas and 2 of the following: (1) family history of PJS; (2) mucocutaneous hyperpigmentation; or (3) small-bowel polyposis.<sup>1</sup> PJS leads to life-threatening complications including lead-point intussusception because of the presence of the polyps and an array of solid tumors.

The genetics of PJS has been the subject of intensive study, and over time it has largely confirmed Jeghers et al<sup>2</sup> prediction of a “single pleiotropic gene.” Germline mutations in the tumor suppressor gene *STK11* are identified in the majority of cases of PJS.<sup>3,4</sup> Although some authors have proposed the existence of other loci, *STK11* has been the only gene known to be associated with PJS. Both heterozygous point mutations and gene deletions of *STK11* are responsible for the PJS phenotype.<sup>5</sup> As molecular technology has advanced, cases which were previously classified as “*STK11* negative” were noted to be due to *STK11* deletions which were not detected by sequencing methods.<sup>5</sup> Recent studies combining diagnostic methods sensitive to deletions and point mutations have suggested that all cases may be due to some type of *STK11* mutation.<sup>6,7</sup> The genotype-phenotype correlation in PJS is complex but higher cancer risk may be associated with mutations in exon 3 or premature truncation alleles.<sup>8</sup> Although *STK11* is the only known gene, there are also no reported cases in which an individual with an *STK11* mutation does not show clinical manifestations leading some authors to suggest that these mutations are fully penetrant.<sup>6</sup> *STK11* is involved in epithelial polarity and in the regulation of proliferative signals of the mTOR pathway through phosphorylation of AMP kinase. The latter observation has led to promising therapeutic insight showing reduced polyp burden in PJS mouse models when treated with the mTOR inhibitor rapamycin.<sup>9</sup>

The gastrointestinal (GI) complications of PJS are significant and because of the possibility of malignant transformation of hamartomatous polyps present in the colon and small bowel, surveillance is recommended.<sup>10</sup> Current guidelines for GI tract surveillance are based on the expected age at onset of small bowel and colon cancers in PJS, generally after the second decade of life.<sup>11</sup> In the pediatric population, GI surveillance is generally not undertaken although screening is recommended with follow-up if positive for polyps.<sup>10</sup> The risk of intussusception is significant for children and young adults with PJS.<sup>8</sup> Because of this, the current recommendations for pediatric PJS patients suggest an initial endoscopy at the age of 8 years to evaluate for risk of obstruction, but subsequent screening which has been proposed involves contrast enema.<sup>12</sup> This is proposed because of the risk of obstruction rather than cancer, and because of the high radiation burden it has not been uniformly adopted. In addition, tumor screening is not regularly initiated until after the age of 18 years.<sup>10</sup>

Here, we report a case of a 13-year-old boy who was first diagnosed with PJS after presenting with lead-point intussusception and was found to have a mucinous adenocarcinoma representing the earliest reported case of

Received for publication May 29, 2012; accepted December 12, 2012. From the Departments of \*Molecular and Human Genetics; †Pediatrics, Section of Hematology Oncology; ‡Pediatrics; §Pathology and Immunology; ¶Surgery, Baylor College of Medicine; §Texas Children’s Hospital, Houston, TX; and #Department of Human Genetics, Emory University School of Medicine, Atlanta, GA.

Supported by 5R01CA138836 to S.E.P. R.S.C. is a St Baldrick’s Foundation Fellow for Childhood Cancer Research. M.F.W. received support from 1 K08 NS076547-01.

M.F.W. and R.C. contributed equally.

The authors declare no conflict of interest.

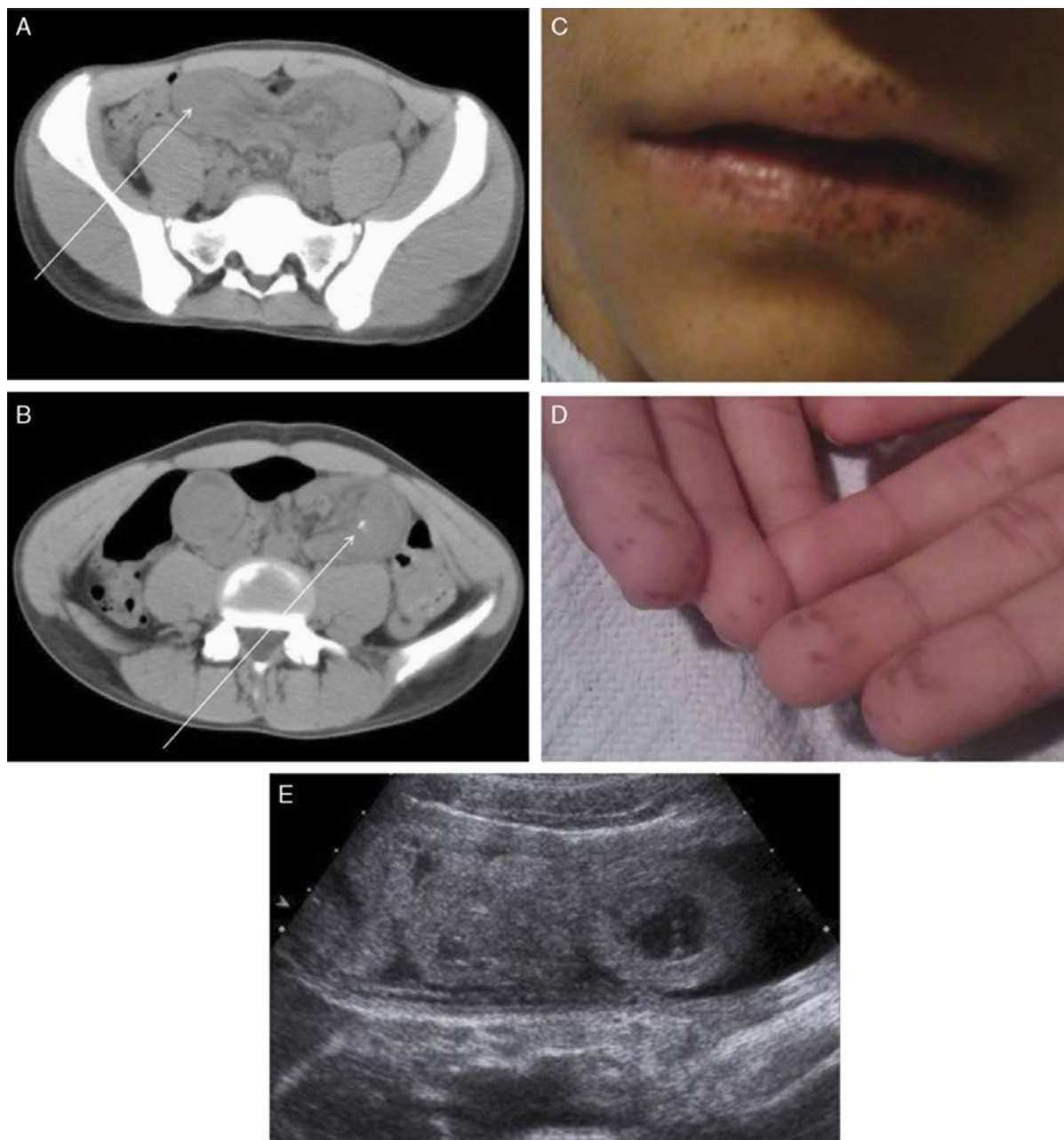
Reprints: Patrick A. Thompson, MD, 6701 Fannin St, Texas Children’s Cancer Center, Houston, TX 77030 (e-mail: pathomps@txch.org). Copyright © 2013 by Lippincott Williams & Wilkins

small-bowel malignancy in PJS. We review the clinical course and the implications for surveillance guidelines for patients with PJS.

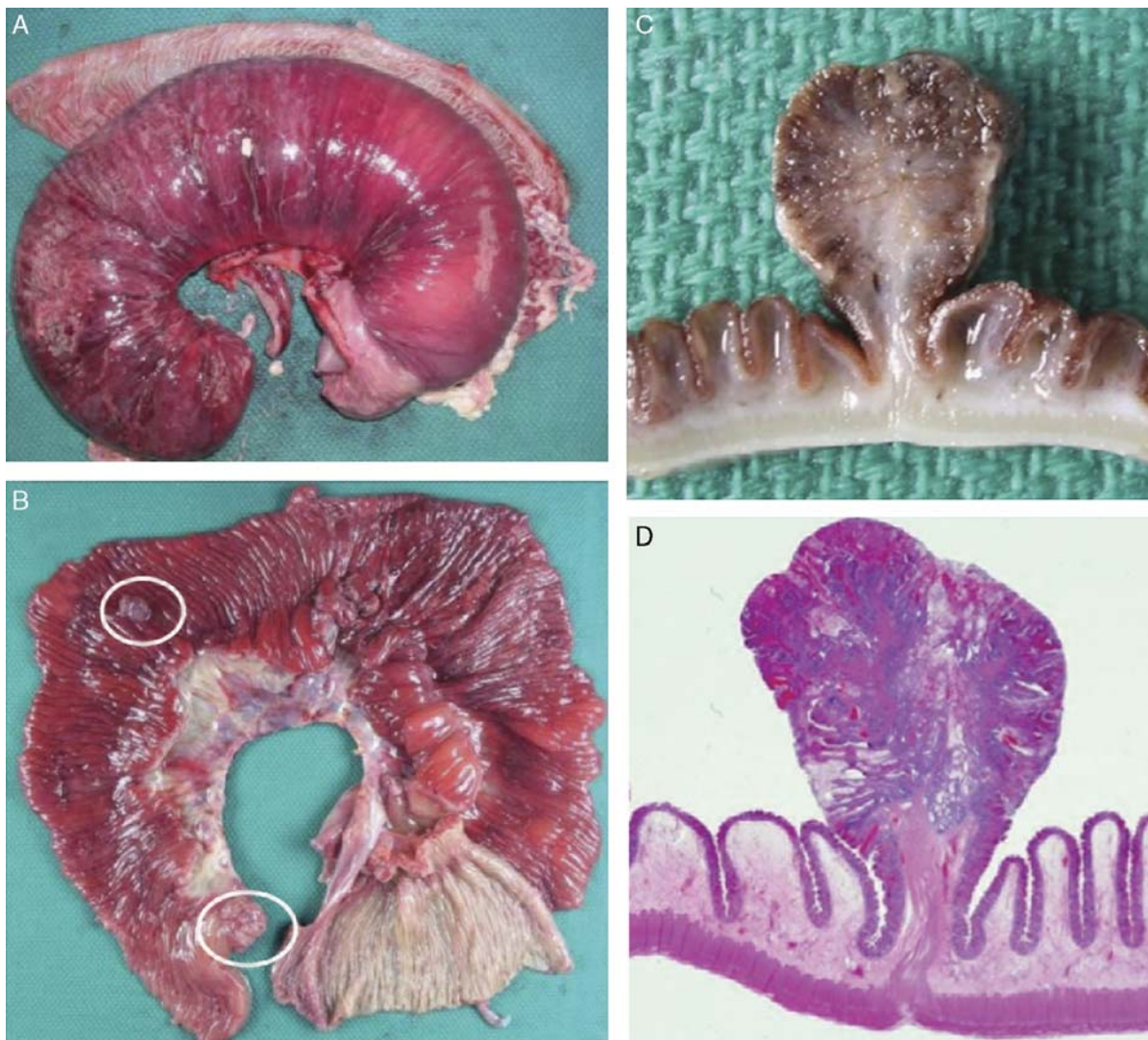### CASE REPORT

A 13-year-old otherwise healthy Hispanic male developed sudden onset periumbilical abdominal pain, which worsened over a 24-hour period. He had associated anorexia, and multiple episodes of watery brown emesis. He presented to an outside emergency

department where a computed tomography scan demonstrated a “U-shaped” pelvic mass (11 × 5 cm) with calcifications, concerning for teratoma or duplication cyst (Figs. 1A, B), and a white blood cell count of 18,000. He was transferred to our institution for evaluation by pediatric surgery. Upon arrival, he was ill appearing. On physical examination the patient was noted to have hyperpigmented macules over the lips, buccal mucosa, and similar macules on the fingertips (Figs. 1C, D). Abdominal ultrasound revealed a large intussusception (Fig. 1E). A comprehensive 4-generation family history included 4 unaffected siblings and



**FIGURE 1.** A, Computed tomography (CT) scan of the abdomen and pelvis at the level of the sacral spine showing a U-shaped mass in the pelvis indicated by the arrow. B, CT scan at the level of the lumbar spine showing the U-shaped mass with a calcification indicated by the arrow. C, Digital photograph of the labial mucosa of the patient revealing the presence of hyperpigmented macules which include some extending beyond the vermilion border. D, Digital photograph of the palmar surface of the patient revealing the presence of hyperpigmented macules on the digits. E, Abdominal ultrasound showing a complex fluid filled structure, which contains within it fluid filled loops of bowel. These findings were diagnostic of a lead-point intussusception.



**FIGURE 2.** Hamartomatous polyp in intussusception in Peutz-Jeghers syndrome. A, Gross specimen of resected small bowel demonstrating intussusception. B, Opened small-bowel resection revealing gross appearance of polyps, indicated by circles C and D, A hamartomatous polyp from the small-bowel resection with both gross (C) and histologic (D) cross-sections demonstrating extension of the smooth muscle layer from the muscularis propria into the core of the polyp, characteristic of a hamartomatous polyp.

unaffected parents. The father’s maternal uncles were reported to have freckles on the face, although neither the father nor his mother had these findings and no photographs were available to confirm this report. There was no family history of GI abnormalities.

The patient was brought to the operating room for a diagnostic laparoscopy that revealed tightly distended loop of small bowel, felt to be small-bowel intussusception. As this segment had to be resected the decision was made to proceed to an open procedure. The mesentery was divided, and the segment was resected and was found to contain small-bowel polyps, one of which was large and a likely pathologic lead-point. After resecting the involved segment an end-to-end anastomosis was performed.

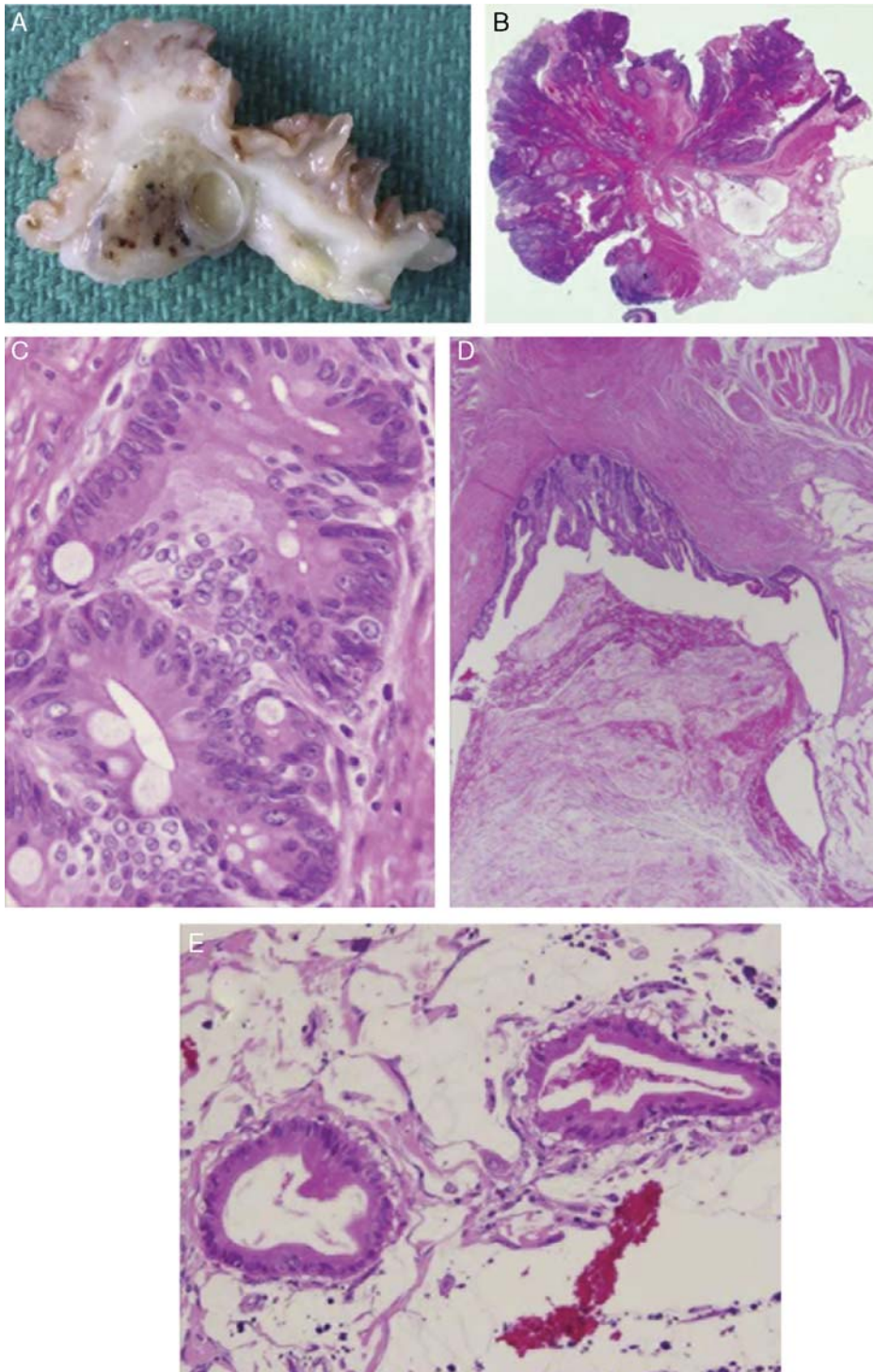
Gross pathologic examination of the resected segment revealed a lead-point intussusception (Fig. 2A). Mucosal polyposis was also evident (Figs. 2B–D). The histology of this hamartomatous polyp was characteristic with extension of the muscularis propria into the substance of the polyp (Fig. 2D). In addition, an invasive mucinous adenocarcinoma was identified (Figs. 3A–D), arising from an area of high-grade dysplasia within one of the

polyps. This tumor was stage IIa (T3, N0, M0) with subserosal invasion (Fig. 3E), and absence of lymph node involvement.

Because of the presence of malignancy, a second operation with small-bowel resection with 10 cm tumor-free surgical margins and expanded lymph node sampling was performed. Follow-up upper and lower endoscopy and imaging revealed additional hamartomatous polyps without evidence of additional primary masses or liver metastases. We concluded based on available evidence that there was no indication for adjuvant chemotherapy or radiation therapy in our patient.<sup>13</sup> Finally, at an office visit 2 years after his initial diagnosis he was well without abdominal pain or other symptoms. He underwent capsule endoscopy approximately 1 year after diagnosis and is currently on a screening regimen involving capsule endoscopy every 2 years with additional studies to follow-up the capsule endoscopy findings.

The patient’s diagnosis of PJS was confirmed by molecular testing. Sequence analysis of the *STK11* gene revealed a heterozygous c.921-1G > T (IVS8-1G > T) mutation. This mutation is pathogenic based on its predicted alteration of the splice acceptor site at the intron 7/exon 8 boundary of the *STK11* gene and by its





**FIGURE 3.** Mucinous adenocarcinoma arising from hamartomatous polyp in Peutz-Jeghers syndrome. A and B, Gross (A) and histologic (B) appearance of hamartomatous polyp with invasive mucinous adenocarcinoma. C, Dysplasia of small-bowel mucosa with a hamartomatous polyp organized into a glandular pattern. D, Invasive mucinous adenocarcinoma from a hamartomatous polyp with invasion of the submucosa, and through the muscularis propria, E, Invasive mucinous adenocarcinoma from a hamartomatous polyp with invasion of the small-bowel serosa.

previous association with PJS.<sup>13</sup> Testing of the parents and siblings of the patient was declined by the family. The clinical impression was that this was a *de novo* case in this family given the highly

penetrant nature of *STK11* mutations and the fact that the parents had never been affected with GI complaints or mucosal pigmentation.

## CONCLUSIONS

Peutz-Jeghers syndrome is an autosomal dominant condition which is thought to have an age-depending predisposition to GI malignancy as well as other types of cancer. Adenocarcinoma in the GI tract is extremely rare in children. The incidence of adenocarcinoma of the colon in children is estimated to be 1 in 10 million.<sup>14</sup> Adenocarcinoma of the colon is associated with a number of genetic conditions in addition to PJS, including familial adenomatous polyposis, Hereditary nonpolyposis colorectal cancer in addition to ulcerative colitis. Children who do develop adenocarcinoma of the colon are diagnosed at a later stage and have more aggressive histology because of delayed diagnosis.<sup>14</sup> Small-bowel adenocarcinoma in children is even rarer with only a handful of cases reported.<sup>15</sup> Patients with PJS have an estimated cumulative risk of small-bowel adenocarcinoma of 13% before the age of 64.<sup>11</sup> The age at onset has varied between studies, but has uniformly been reported after the second decade.<sup>11,16</sup> In a study of 30 patients with PJS from Korea, 4 probands and 4 first-degree relatives of an affected proband had small-bowel cancer, with an overall mean age at onset of cancer of 36 years.<sup>17</sup> In a large study of 240 patients with *STK11* mutations who were ascertained by positive family history of PJS, there was a 66% cumulative risk of all GI tumors, however, all occurred after age 20 years.<sup>16</sup> An extension of this study that included additional cases brought the total number of patients up to 419, but without any GI cancers before the age of 20 years.<sup>18</sup> There is only one report in the literature of a preadolescent with GI cancer in PJS, and in this case the patient had colon cancer.<sup>19</sup>

The absence of such early-onset small-bowel cancers in the literature raises the question of whether our patient's specific *STK11* mutation is unique and could have a stronger association with early-onset cancer. This specific splice site mutation has been reported in 2 other patients with PJS, both of which were familial.<sup>13</sup> In one of these patients a family history of colon cancer was reported, although the proband did not have cancer.<sup>13</sup> The age of these patients at the time of the study was not reported as it focused on identifying novel mutations. Clearly, further studies would be needed to provide evidence of a unique association between this specific mutation and age at onset of cancer. Currently, the genotype-phenotype relationship in PJS suggests that more severe mutations such as deletions may predispose to an earlier age of cancer than missense mutations.<sup>8</sup> At present the genotype does not affect the screening guidelines for patients with PJS. Another possibility to explain a severe phenotype in an otherwise monogenic disease like PJS would be the presence of modifiers. However, there are no other known loci that affect or influence PJS and a much larger study would be required to ascertain modifiers of cancer risk in patients with *STK11* mutations.

Given the extremely high lifetime relative risk of cancer in PJS including small intestinal malignancy screening guidelines are important to assist clinicians in caring for these patients. Screening and surveillance guidelines for GI tumors in PJS are available.<sup>10</sup> For pediatric patients, however, regular screening is not uniform and its purpose is to avoid urgent laparotomy rather than screen for malignancy. Current recommendations call for upper and lower endoscopy at age 8 years in patients with PJS, and then at age 18 years followed by every 2 to 3 years.<sup>10</sup> Screening from 8 to 18 years with barium-contrast enema has been

proposed but has not been adopted. The recommendation for the initial screening at 8 years of age in asymptomatic cases of PJS is based on a review of 51 cases of PJS where 30% of the patients had already required a laparotomy by 10 years of age.<sup>12</sup> Of the total laparotomies reported in the review 70% of the initial laparotomies were performed urgently for intestinal obstruction mainly because of the presence of small-bowel polyps. On the basis of our case and the other case of a child with PJS and GI cancer,<sup>19</sup> we propose that guideline for cancer screening in this age group are called for. Capsule endoscopy allows the unique advantages of a full survey of the GI tract and does not have the radiation risks of barium studies. A screening program involving capsule endoscopy every 2 years in patients with PJS between ages 8 and 18 years would be reasonable and could be studied for efficacy. Children with PJS are also at risk for intestinal obstruction such that patients and parents should be aware of the need for prompt medical attention if acute abdominal pain develops. Our case represents the earliest reported case of small-bowel cancer in PJS at the age of 13 years and suggests that between ages 8 and 18, there is a certain risk of malignancy that could be screened for using semiannual capsule endoscopy in adolescent patients with PJS.<sup>20</sup>

## REFERENCES

1. McGarrity TJ, Amos C. Peutz-Jeghers syndrome: clinicopathology and molecular alterations. *Cell Mol Life Sci*. 2006; 63:2135–2144.
2. Jeghers H, Mc KV, Katz KH. Generalized intestinal polyposis and melanin spots of the oral mucosa, lips and digits; a syndrome of diagnostic significance. *N Engl J Med*. 1949;241: 993, illust; passim.
3. Hemminki A, Markie D, Tomlinson I, et al. A serine/threonine kinase gene defective in Peutz-Jeghers syndrome. *Nature*. 1998;391:184–187.
4. Jenne DE, Reimann H, Nezu J, et al. Peutz-Jeghers syndrome is caused by mutations in a novel serine threonine kinase. *Nat Genet*. 1998;18:38–43.
5. Aretz S, Stienen D, Uhlhaas S, et al. High proportion of large genomic *STK11* deletions in Peutz-Jeghers syndrome. *Hum Mutat*. 2005;26:513–519.
6. Chow E, Meldrum CJ, Crooks R, et al. An updated mutation spectrum in an Australian series of PJS patients provides further evidence for only one gene locus. *Clin Genet*. 2006;70: 409–414.
7. Papp J, Kovacs ME, Solyom S, et al. High prevalence of germline *STK11* mutations in Hungarian Peutz-Jeghers Syndrome patients. *BMC Med Genet*. 2010;11:169.
8. Amos CI, Keitheri-Cheteri MB, Sabripour M, et al. Genotype-phenotype correlations in Peutz-Jeghers syndrome. *J Med Genet*. 2004;41:327–333.
9. Wei C, Amos CI, Zhang N, et al. Chemopreventive efficacy of rapamycin on Peutz-Jeghers syndrome in a mouse model. *Cancer Lett*. 2009;277:149–154.
10. Giardiello FM, Trimbath JD. Peutz-Jeghers syndrome and management recommendations. *Clin Gastroenterol Hepatol*. 2006;4:408–415.
11. Giardiello FM, Brensinger JD, Tersmette AC, et al. Very high risk of cancer in familial Peutz-Jeghers syndrome. *Gastroenterology*. 2000;119:1447–1453.
12. Hinds R, Philp C, Hyer W, et al. Complications of childhood Peutz-Jeghers syndrome: implications for pediatric screening. *J Pediatr Gastroenterol Nutr*. 2004;39:219–220.
13. Ylikorkala A, Avizienyte E, Tomlinson IP, et al. Mutations and impaired function of *LKB1* in familial and non-familial Peutz-Jeghers syndrome and a sporadic testicular cancer. *Hum Mol Genet*. 1999;8:45–51.

14. Blumer SL, Anupindi SA, Adamson PC, et al. Sporadic adenocarcinoma of the colon in children: case series and review of the literature. *J Pediatr Hematol Oncol*. 2012;34:e137–e141.
15. Tankel JW, Galasko CS. Adenocarcinoma of small bowel in 12-year-old girl. *J R Soc Med*. 1984;77:693–694.
16. Lim W, Olschwang S, Keller JJ, et al. Relative frequency and morphology of cancers in STK11 mutation carriers. *Gastroenterology*. 2004;126:1788–1794.
17. Choi HS, Park YJ, Youk EG, et al. Clinical characteristics of Peutz-Jeghers syndrome in Korean polyposis patients. *Int J Colorectal Dis*. 2000;15:35–38.
18. Hearle N, Schumacher V, Menko FH, et al. Frequency and spectrum of cancers in the Peutz-Jeghers syndrome. *Clin Cancer Res*. 2006;12:3209–3215.
19. Saranrittichai S. Peutz-Jeghers syndrome and colon cancer in a 10-year-old girl: implications for when and how to start screening? *Asian Pac J Cancer Prev*. 2008;9:159–161.
20. Ohmiya N, Nakamura M, Takenaka H, et al. Management of small-bowel polyps in Peutz-Jeghers syndrome by using enteroclysis, double-balloon enteroscopy, and videocapsule endoscopy. *Gastrointest Endosc*. 2010;72:1209–1216.